Surgical Interventions for Secondary Stroke Prevention

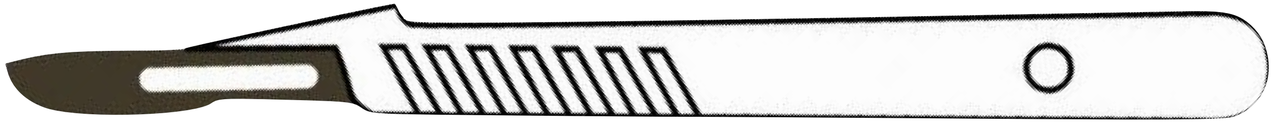

Saurav Das, MD
Assistant Professor
Vascular Neurology
University of Kentucky College of Medicine

Disclosures

None relevant to this talk

Objectives

- Discuss current thoughts on surgical interventions for secondary stroke prevention after discharge.
- Review surgical Interventions for secondary stroke prevention.
- Translate these interventions to use in clinical practice.

Is this important ?

“I remember seeing an elaborate and complicated automatic washing machine for automobiles that did a beautiful job of washing them. But it could do only that, and everything else that got into its clutches was treated as if it were an automobile to be washed. *I suppose it is tempting, if the only tool you have is a hammer, to treat everything as if it were a nail.*”

Abraham Maslow
Psychology of Science, 1966

Is this new?

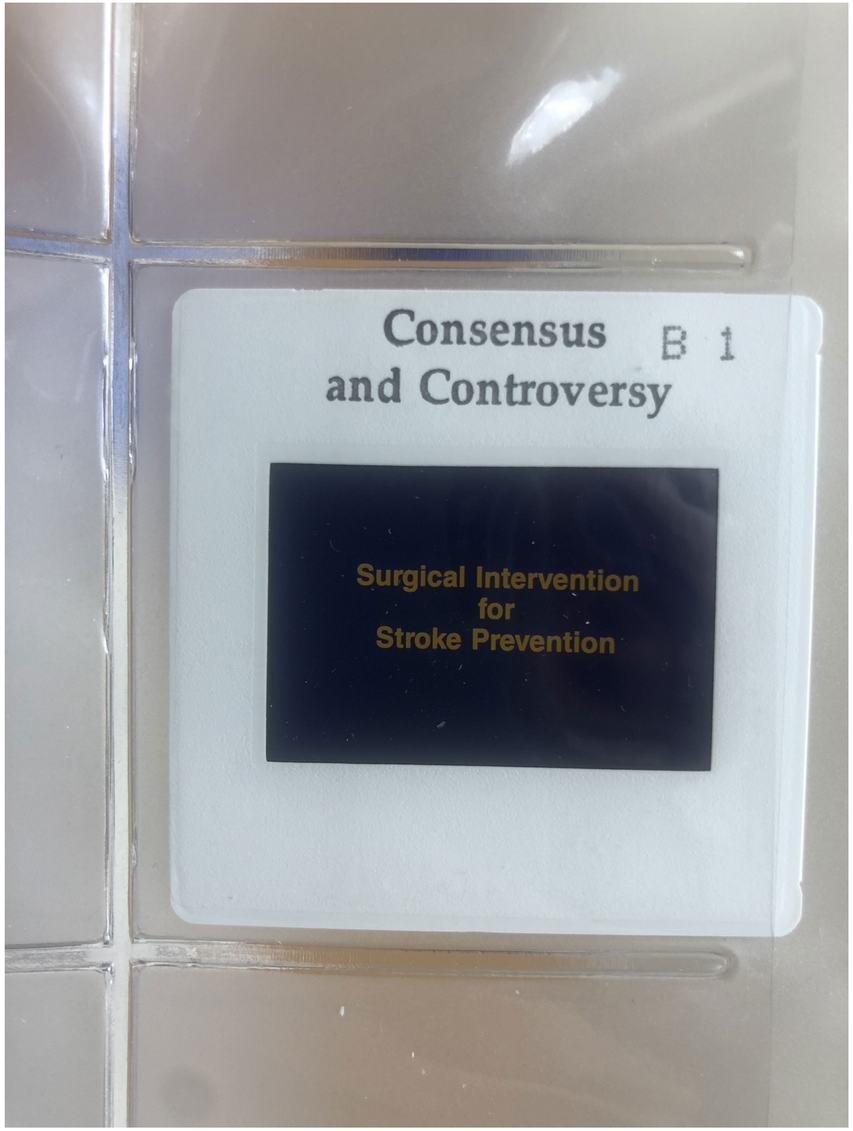

Stroke
Volume 27, Issue 8, August 1996; Pages 1427-1434
https://doi.org/10.1161/01.STR.27.8.1427

American Heart Association.

ARTICLE

The Evolution of Surgery for the Treatment and Prevention of Stroke

The Willis Lecture

Jesse E. Thompson



Outline

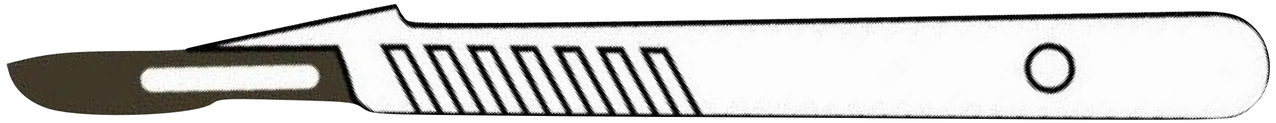

1. Carotid Endarterectomy
2. Carotid Artery Stenting
3. Extracranial- Intracranial Bypass Surgery
4. Trans Carotid Artery Revascularization
5. Patent Foramen Ovale Closure
6. Left Atrial Appendage Closure
7. Catheter ablation for Atrial Fibrillation

Patient 1 *(pre).*

Mr. A is a 65 year old man who presents to ED with recurrent episodes of transient feeling of a **curtain falling over the left eye in the last 2 weeks**. His neurological examination is normal. CT Angiogram of head and neck is significant for **80% stenosis of left internal carotid artery** and **complete occlusion of right internal carotid artery** at its origin. MRI of the brain shows **small old watershed infarcts on the right side**. Which of the following is preferred management in this patient ?

A. Medical Management only
B. Extracranial-Intracranial bypass surgery for right Internal Carotid Artery
C. Carotid Endarterectomy for left Internal Carotid Artery
D. Carotid Artery Stenting for left Internal Carotid Artery

slido

Which of the following is preferred management in this patient ?

ⓘ Start presenting to display the poll results on this slide.

Carotid Intervention for Stroke Prevention

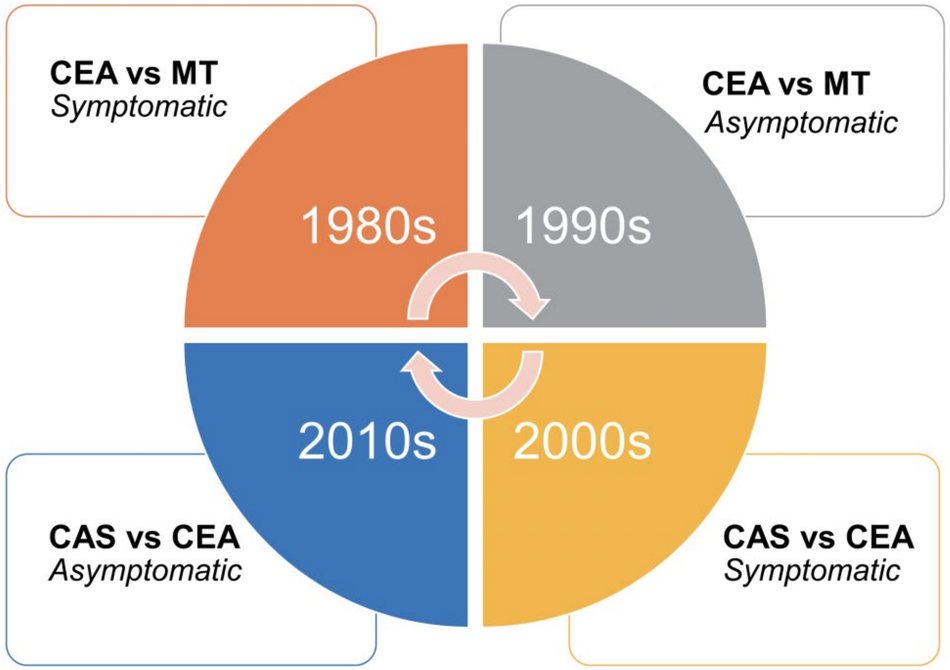

Fig. 1. The cycle of large-scale carotid intervention trials.

The long-term efficacy and procedural risks of carotid interventions have been assessed over four decades of large, randomised clinical trials. With improvements in best medical therapy, carotid surgery is again being compared to best medical therapy alone in people with symptomatic and asymptomatic carotid stenosis. CEA, carotid endarterectomy; MT, medical therapy; CAS, carotid artery stenting.

Morris, D., et al.J Atheroscler Thromb, 2017; 24: 373-387.

Carotid Endarterectomy for Stroke Prevention in Symptomatic Carotid Stenosis

Table 1. Randomised clinical trials comparing carotid endarterectomy to medical therapy alone in patients with carotid artery stenosis.

Trial	Recruitment	*n*	Follow-up	Procedural Hazards			Long-term Stroke Rate			*p*-value
				Definition	CEA	MT	Definition	CEA	MT	
Symptomatic										
VA309	1988-1991	189	Mean 1.0 year	30d crescendo TIA, stroke & death	6.6%	6.1%	Ipsilateral stroke, crescendo TIA or perioperative death	7.7%	19.4%	0.028
ECST-1 (≥80%)	1981-1994	574 (of 3024)	Mean 6.1 years	30d major stroke & death	4.5%	0%	Ipsilateral stroke or perioperative death	6.8%	20.6%	<0.0001
NASCET (≥70%)	1987-1991	659	Mean 1.5 years	30d stroke & death	5.8%	3.3%	Ipsilateral stroke	9.0%	26.0%	<0.001
NASCET (50-69%)	1987-1996	858	5 years	30d stroke & death*	6.7%	2.4%	Ipsilateral stroke	15.7%	22.2%	0.045

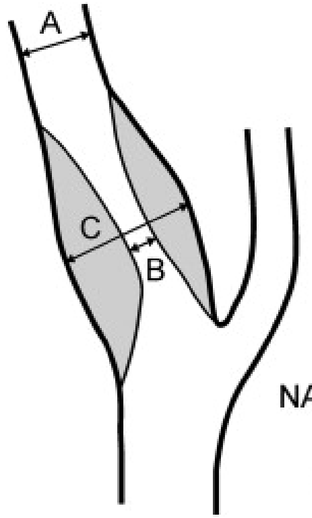

$$\text{NASCET} = \frac{A-B}{A}$$

$$\text{ECST} = \frac{C-B}{C}$$

ECST= 0.6 NASCET +40%

ARTICLES

Analysis of pooled data from the randomised controlled trials of endarterectomy for symptomatic carotid stenosis

P M Rothwell, M Eliasziw, S A Gutnikov, A J Fox, D W Taylor, M R Mayberg, C P Warlow, H J M Barnett, for the Carotid Endarterectomy Trialists' Collaboration

Degree of Stenosis	ARR
<30%	-2.2%*
30-49%	3.2%
50-69%	4.6%*
>70%	16%*
Near Occlusion	5.6%

Best benefit within 2 weeks of incident stroke

Rothwell, P., et al.The Lancet, 2011; 361: 107-116.

Carotid Artery Stenting for Stroke Prevention in Symptomatic Carotid Stenosis

Trial	Recruitment	*n*	Follow-up	Procedural Hazards				Long-Term Stroke Rate			
				Definition	CEA	CAS	*p*-value	Definition	CEA	CAS	*p*-value
Symptomatic											
CAVATAS	1992-1997	504	Median 5 years	30d disabling stroke & death	5.9%	6.4%	N.S.	Any stroke & periprocedural death	23.5%	29.7%	n.s.
SAPPHIRE (subgroup)	2000-2002	96	78% at 3 years*	30d MI, stroke, death	9.3%	2.1%	0.18	Periprocedural MI, stroke, death & post-procedural ipsilateral stroke & death	21.7%	32.0%	N.R.
EVA-3S	2000-2005	527	Median 3.5 years	30d stroke & death	3.9%	9.6%	0.01	Periprocedural stroke, death, & post-procedural ipsilateral stroke	6.2%	11.1%	0.03
SPACE-1	2001-2006	1214	2 years	30d ipsilateral stroke & death	6.5%	6.9%	0.09†	Periprocedural stroke, death, & post-procedural ipsilateral stroke	8.8%	9.5%	0.62
ICSS	2001-2008	1713	Median 4.2 years	30d procedural MI, stroke, death	4.0%	7.4%	0.003	Fatal or disabling stroke	6.5%	6.4%	0.77
CREST-1 (subgroup)	2000-2008	1321	Median 7.4 years*	30d MI, stroke, death	5.4%	6.7%	n.s.	Periprocedural MI, stroke, death & postprocedural ipsilateral stroke	5y: 8.7% 10y: 9.8%	5y: 9.0% 10y: 13.4%	0.40

High procedural stroke rates
Varying level of technical expertise
Use of embolic protection device

Short-term outcome after stenting versus endarterectomy for symptomatic carotid stenosis: a preplanned meta-analysis of individual patient data

*Carotid Stenting Trialists' Collaboration**

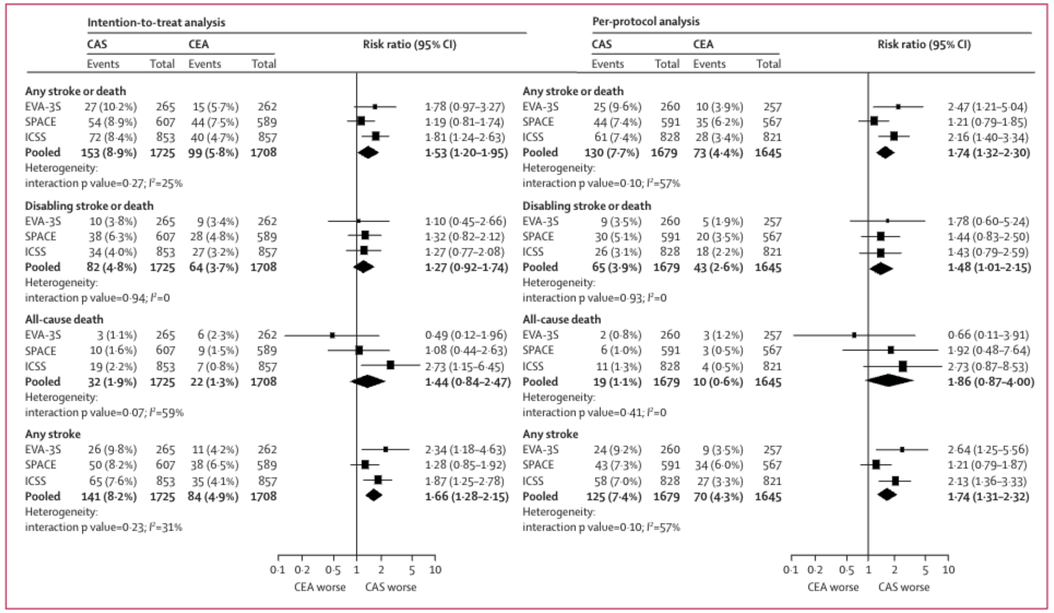

Carotid Stenting Trialists Collaboration.The Lancet, 2010; 376: 1062-73.

Carotid Artery Stenting for Stroke Prevention in Symptomatic Carotid Stenosis

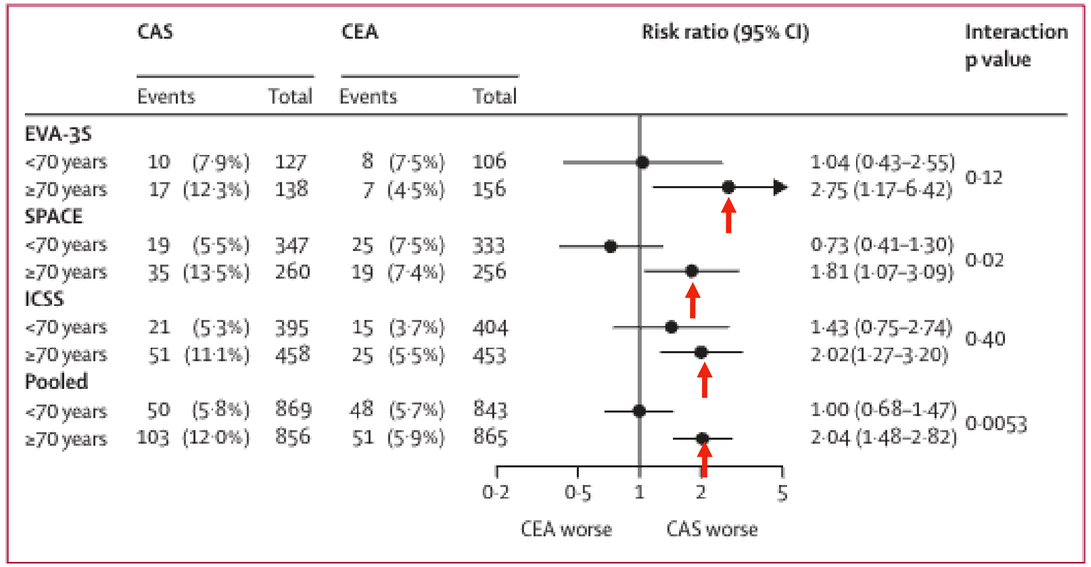

Carotid Stenting Trialists Collaboration.The Lancet, 2010; 376: 1062-73.

Carotid Artery Stenting for Stroke Prevention in Symptomatic Carotid Stenosis

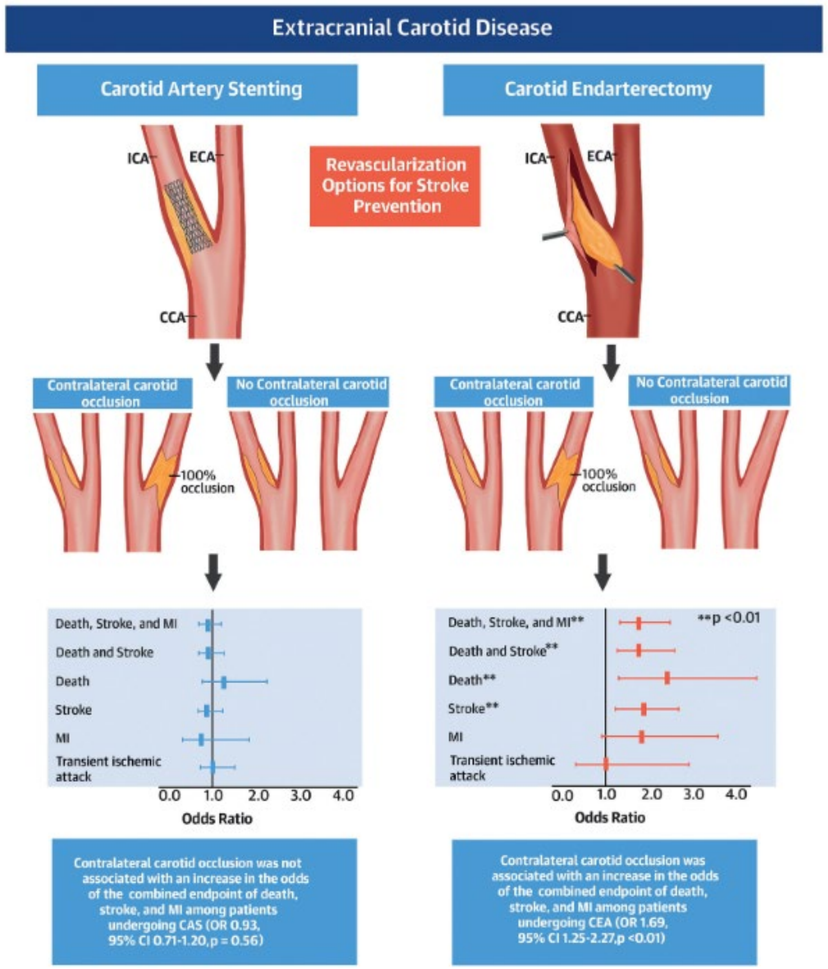

Krawisz, A.K. et al. J Am Coll Cardiol. 2021;77(7):835-44.

Sex- Female
Contralateral stenosis
Age <75 years
Restenosis

Touze, E., et al. Stroke, 2013; 44:3394-3400.

Carotid Endarterectomy for Asymptomatic Carotid Stenosis

Trial	Recruitment	*n*	Follow-up	Procedural Hazards			Long-term Stroke Rate			*p*-value
				Definition	CEA	MT	Definition	CEA	MT	
Asymptomatic										
VA trial	1983-1987	444	Mean 4.0 years	30d permanent stroke & death	4.7%	1.3%	Ipsilateral TIA, transient monocular blindness, stroke	8.0%	20.6%	<0.001
ACAS	1987-1993	1662	Median 2.7 years	30d stroke & death	2.3%	0.4%	Periprocedural stroke or death, and post-operative ipsilateral stroke	5.1%	11.0%	0.004
ACST-1	1993-2003	3120	Median 6.1 years	30d stroke & death	2.6%	0.7%	Any stroke or perioperative death	5y: 6.9% 10y: 13.4%	5y: 10.9% 10y: 17.9%	5y: 0.0001 10y: 0.009

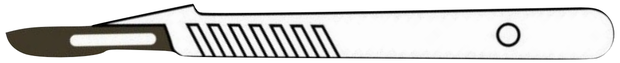

Selection of skilled interventionists
Introduction of Triple Therapy

Carotid Artery Stenting for Asymptomatic Carotid Stenosis

Trial	Recruitment	*n*	Follow-up	Procedural Hazards				Long-Term Stroke Rate			
				Definition	CEA	CAS	*p*-value	Definition	CEA	CAS	*p*-value
Asymptomatic											
SAPPHIRE (subgroup)	2000-2002	237	78% at 3 years*	30d MI, stroke, death	10.2%	5.4%	0.20	Periprocedural MI, stroke, death & post-procedural ipsilateral stroke, death	29.2%	21.4%	N.R.
CREST-1 (subgroup)	2000-2008	1181	Median 7.4 years*	30d MI, stroke, death	3.6%	3.5%	n.s.	Periprocedural MI, stroke, death & postprocedural ipsilateral stroke	5y: 5.4% 10y: 10.1%	5y: 6.1% 10y: 9.6%	0.95
ACT I	2005-2013	1453	Up to 5 years	30d MI, stroke, death	2.6%	3.3%	0.60†	Post-procedural ipsilateral stroke	2.7%	2.2%	0.51†
SPACE-2	2009-2014	513	Ongoing	30d stoke, death	1.97%	2.54%	N.R.	Periprocedural stroke, death & post-procedural ipsilateral stroke		Pending	

Low Stroke Rates
(e.g. 10 year stroke risk was 10% in CREST)
Require larger trials to minimize impact of random error.

Morris, D., et al.J Atheroscler Thromb, 2017; 24: 373-387.

Screening for Asymptomatic Carotid Stenosis

1. Specificity of Carotid Ultrasound (88-94% for CAS >50%to 70%)
Screening in low prevalence population may yield false positive results.

2. Meta-analysis of RCTs comparing CEA vs CAS shows 5.5% absolute risk reduction of non-preoperative stroke over 5 years.

3. Rate of preoperative stroke/ death after procedure regardless of comparator is 2.4 % in the meta-analysis of all CEA trials.

4. Rates of perioperative stroke rates were similar of slightly higher for CAS compared to CEA.

What does the USPSTF recommend?	**For the general adult population:** **Do not screen** for asymptomatic carotid artery stenosis. **Grade D**

Jonas, D., et al. AHRQ; 2014 (Evidence Syntheses, No. 111)

USPSTF, JAMA. 2021; 325:476-81

Approach to Management of Carotid Artery Stenosis

Symptoms	Degree of Stenosis	Context	Management
Symptomatic	70-99%	Sex- Female Contralateral Stenosis Age >75 years Restenosis Radiation induced stenosis Surgically inaccessible lesion	Consider CAS within 2 weeks of event when possible
	70-99%	Male Surgically accessible lesion Above absent	Consider CEA within 2 weeks of event when possible
	50-69%	Male	CEA within 2 weeks of event when possible
		Female	Medical Management
	<50%	All	Medical Management
Asymptomatic	60-99%	Male Peri-operative Stroke/Death <3%	CEA may be acceptable in highly selective patients

Approach to Carotid Artery Occlusion

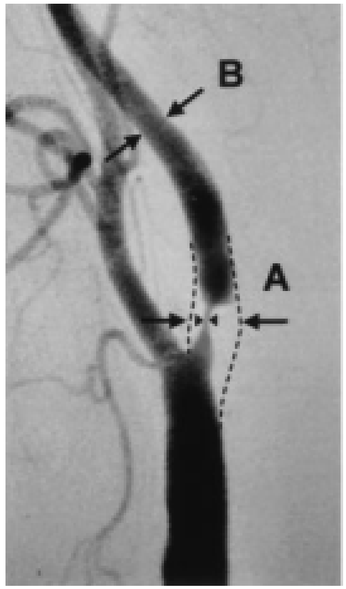

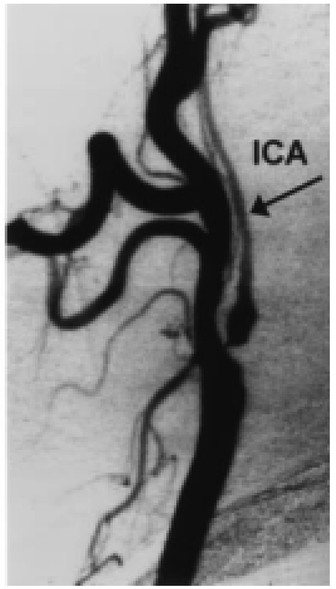

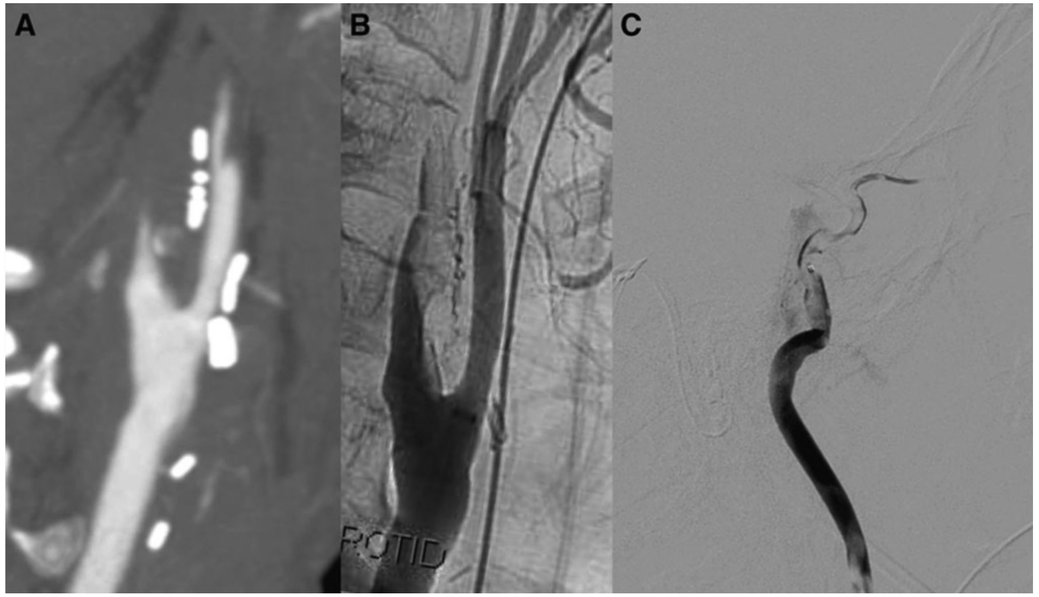

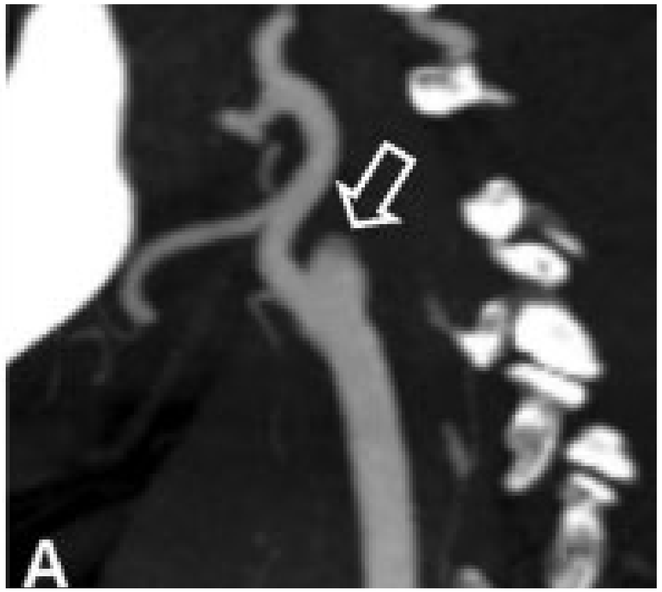

Near Occlusion

Pseudo Occlusion

True Occlusion

Rothwell, P., et al.Stroke, 2003; 34(2) 514-523.

Grossberg, J., et al. Stroke, 2017; 48: 774-777

Approach to Carotid Artery Occlusion

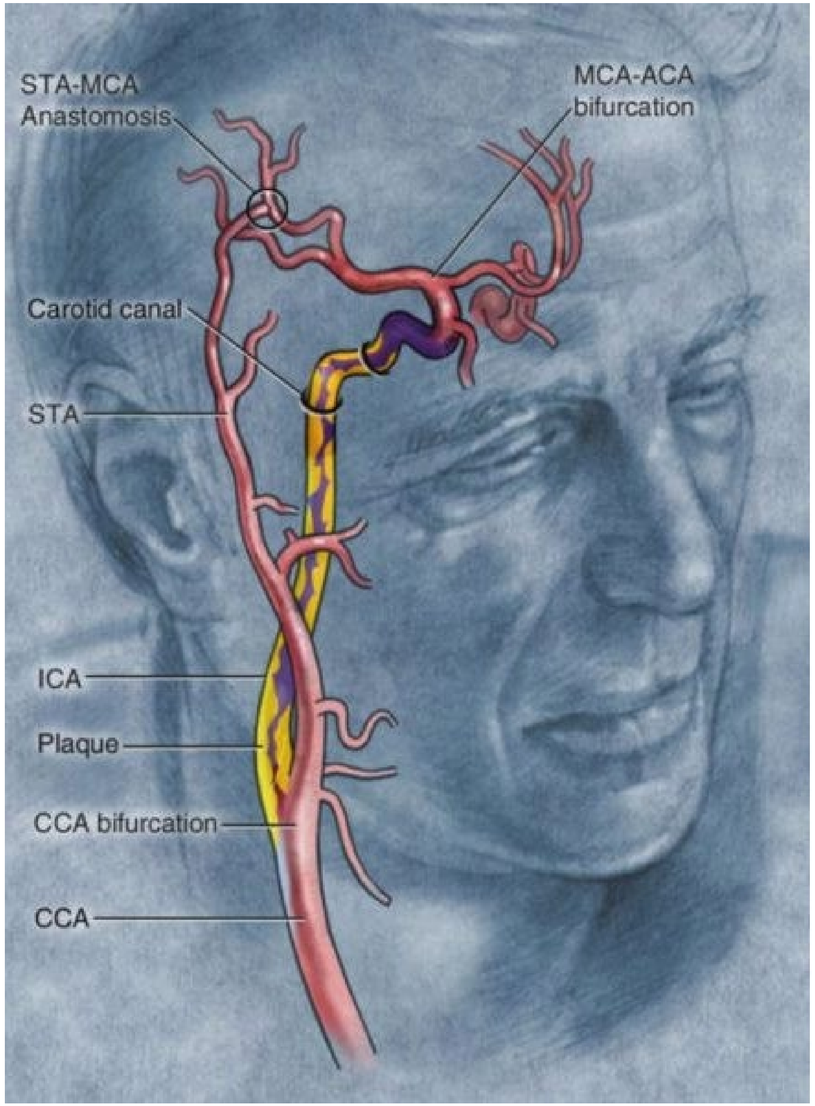

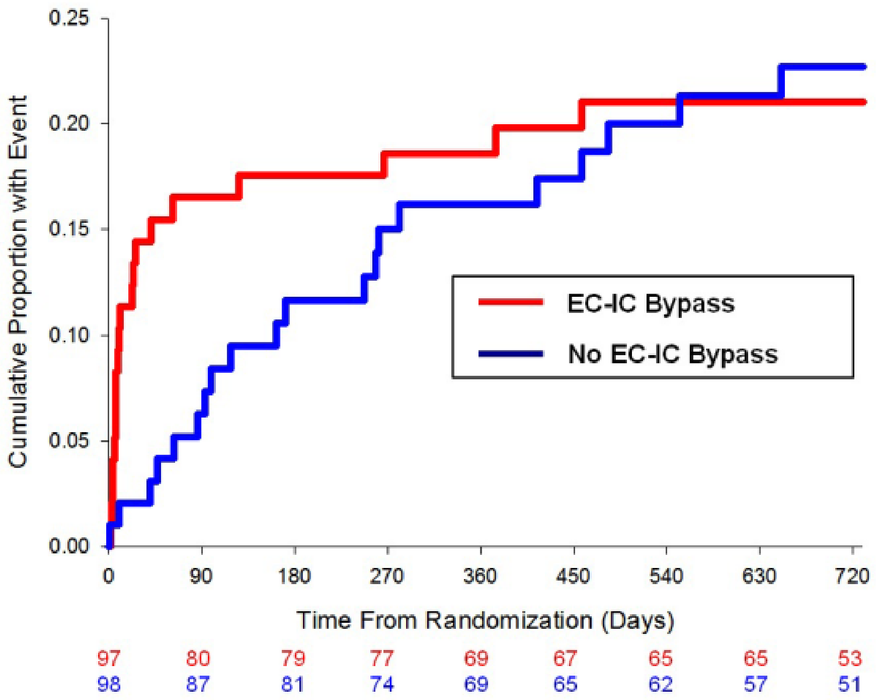

COSS Study
Similar 2 year stroke-TIA recurrence rate

barrowneuro.org

Powers, W., et al. JAMA.2011; 306(18):1983-92

Institutional Volume

	FY20	FY21	FY22
CEA (Neurosurgery, Vascular, CT Surgery)	40	39	37
CAS (Neuro-IR, Cardiology, Vascular)	49	52	68

Patient 1 *(post)*.

Mr. A is a 65 year old man who presents to ED with recurrent episodes of transient feeling of a **curtain falling over the left eye in the last 2 weeks**. His neurological examination is normal. CT Angiogram of head and neck is significant for **80% stenosis of left internal carotid artery** and **complete occlusion of right internal carotid artery** at its origin. MRI of the brain shows **small old watershed infarcts on the right side**. Which of the following is preferred management in this patient ?

A. Medical Management only
B. Extracranial-Intracranial bypass surgery for right Internal Carotid Artery
C. Carotid Endarterectomy for left Internal Carotid Artery
D. Carotid Artery Stenting for left Internal Carotid Artery

slido

Which of the following is preferred management in this patient ?

ⓘ Start presenting to display the poll results on this slide.

Patient 1 *(brainstorm)*.

Mr. A is a 65 year old man who presents to ED with recurrent episodes of transient feeling of a **curtain falling over the left eye in the last 2 weeks**. His neurological examination is normal. CT Angiogram of head and neck is significant for **80% stenosis of left internal carotid artery** and **complete occlusion of right internal carotid artery** at its origin. MRI of the brain shows **small old watershed infarcts on the right side**.

1. Is the left ICA symptomatic? **Yes**, because it is causing TIAs. Ophthalmic artery is a branch of ICA.
2. Is the right ICA symptomatic? **Can't tell**. The watershed strokes on MRI appear to be covert and could have happened within or beyond 6 months.
3. Does evidence favor EC-IC bypass for occluded ICA? **No**. COSS trial.
4. In patients with symptomatic carotid stenosis (left here) and concomitant contralateral carotid occlusion, does evidence favor CEA or CAS? **CAS**. SCAR Rule.

Patient 1*(Answer)*.

Mr. A is a 65 year old man who presents to ED with recurrent episodes of transient feeling of a **curtain falling over the left eye in the last 2 weeks**. His neurological examination is normal. CT Angiogram of head and neck is significant for **80% stenosis of left internal carotid artery** and **complete occlusion of right internal carotid artery** at its origin. MRI of the brain shows **small old watershed infarcts on the right side**.

A. Medical Management only
B. Extracranial-Intracranial bypass surgery for right Internal Carotid Artery
C. Carotid Endarterectomy for left Internal Carotid Artery
D. Carotid Artery Stenting for left Internal Carotid Artery

The Ghost of NASCET!!

COMMENTARY

Luca Bartolini, MD, Section Editor

Practice Current

How do you manage patients with a "hot carotid"?

Aravind Ganesh, MD, DPhil, John H. Wong, MD, MSc, FRCSC, and Bijoy K. Menon, MD, MSc, FRCPC

Neurology: Clinical Practice December 2018 vol. 8 no. 6 527-536 doi:10.1212/CPJ.0000000000000562

Correspondence
Dr. Ganesh
aravindganeshy@yahoo.ca

Initial results from NASCET were published in 1991. At that time, clopidogrel was not in use, high-potency statins were not available, CAS was still being refined, and management of blood pressure was suboptimal.

Is there any other area of modern neurology where patients are treated on the basis of data that are 28 years old? Some neurology trainees were not even born in 1991, yet the ghost of NASCET marches forward in clinical practice guidelines.

CREST-2

Chaturvedi, S. Neurology CP. 2018; 8(6): 466-67

Trans Carotid Artery Revascularization (TCAR)

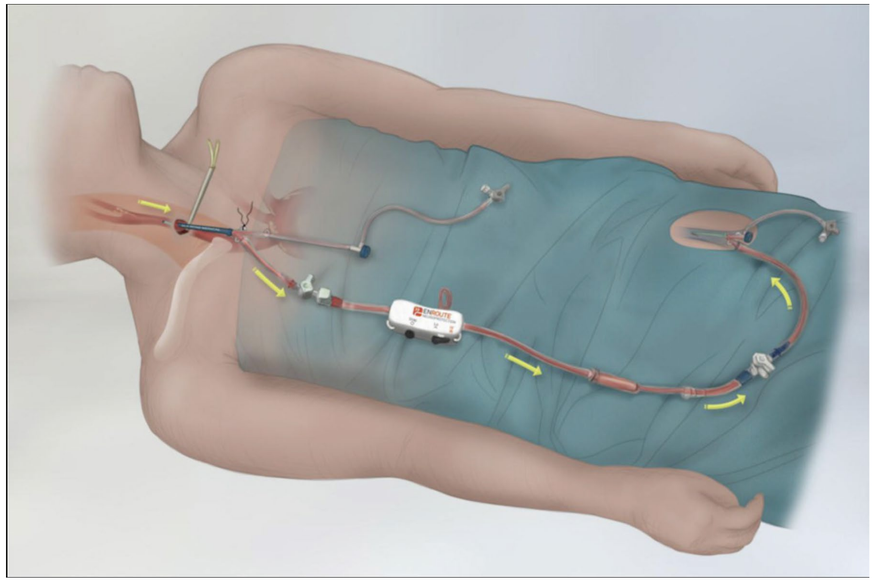



ROADSTER 1: ENROUTE transcarotid neuroprotection system with variety of stents
ROADSTER 2: ENROUTE transcarotid neuroprotection system with ENROUTE transcarotid stent

Conclusion:
At 1 year post-procedurally, no ipsilateral strokes or neurological deaths occurred in 155 patients who underwent transcarotid artery revascularization (23% symptomatic) across 22 centers globally. All patients were at high risk for carotid surgery.

Limitation:
Of 632 patients enrolled, only 166 consented to the long term follow up phase past 30 days. 11 were excluded due to protocol deviation (medication non-adherence).

Kashyap, V. J Vasc Surgery. 2022;76: 466-73

Patient 2 *(pre).*

Ms. A is a 55 year old woman with no past history apart from **morbid obesity and migraine with aura** that appears to be well controlled with Erenumab (*aimovig*), presents to ED with acute onset right hand weakness. CT Angiogram of head and neck is normal apart from mild calcifications at bilateral carotid bifurcation. MRI of the brain showed a **small cortical infarct involving the left hand knob area (image)**. A trans-thoracic echocardiogram was normal but a **trans-esophageal echocardiogram showed a small PFO**. She neither has evidence of venous thrombosis in lower extremity, nor a pro coagulable state. Which of the following is the best answer for this patient ?

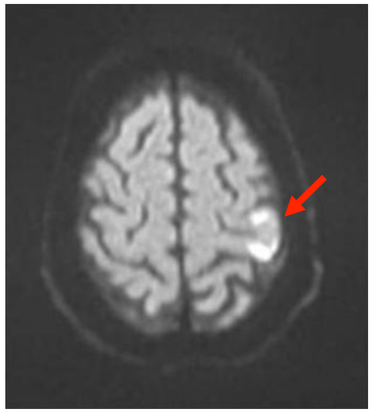

A. No PFO Closure because the PFO is small.
B. Aspirin, Statin, Cardiac monitoring for detection of occult atrial fibrillation.
C. Anticoagulation because cortical strokes are embolic.
D. Close PFO. PFO closure also helps treatment of migraine with aura.

slido

Which of the following is the best answer for this patient ?

ⓘ Start presenting to display the poll results on this slide.

Patent Foramen Ovale

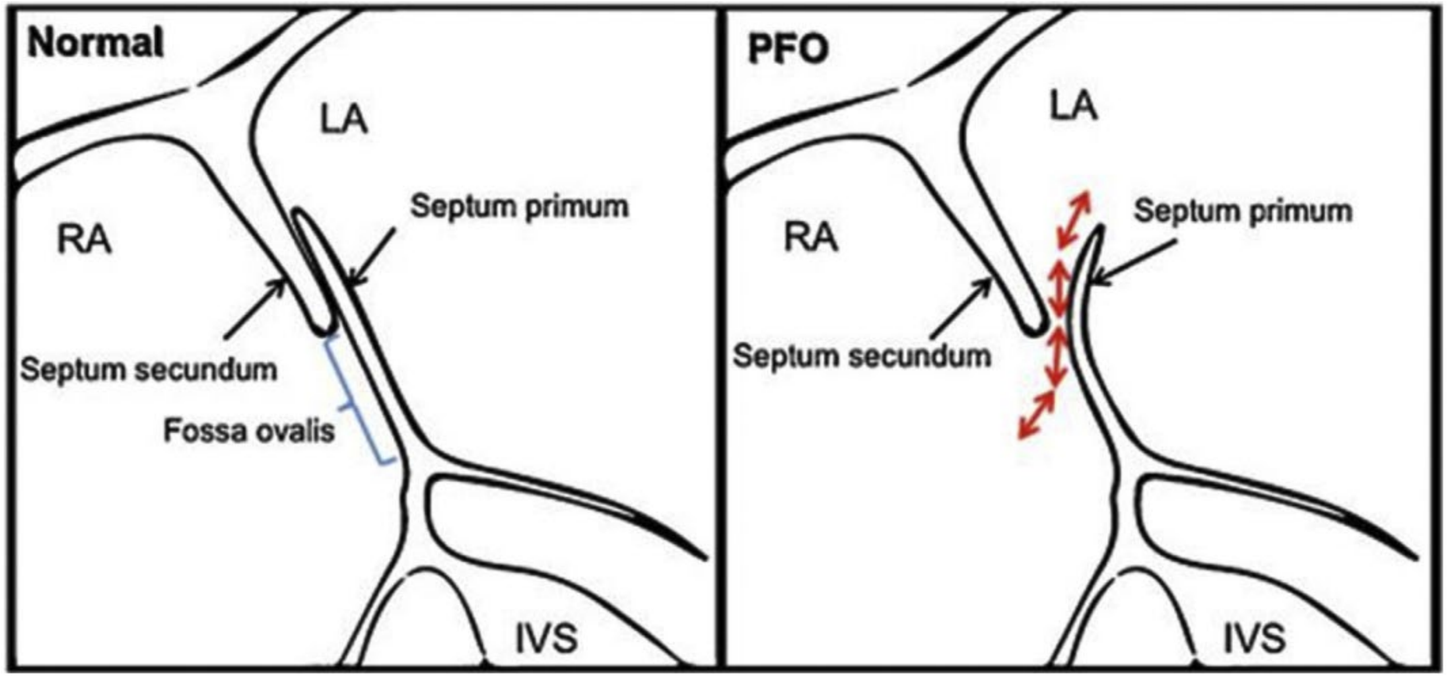

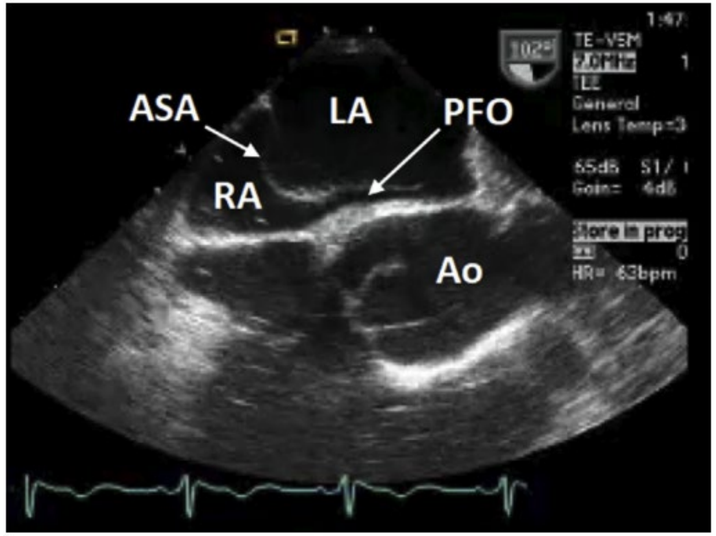

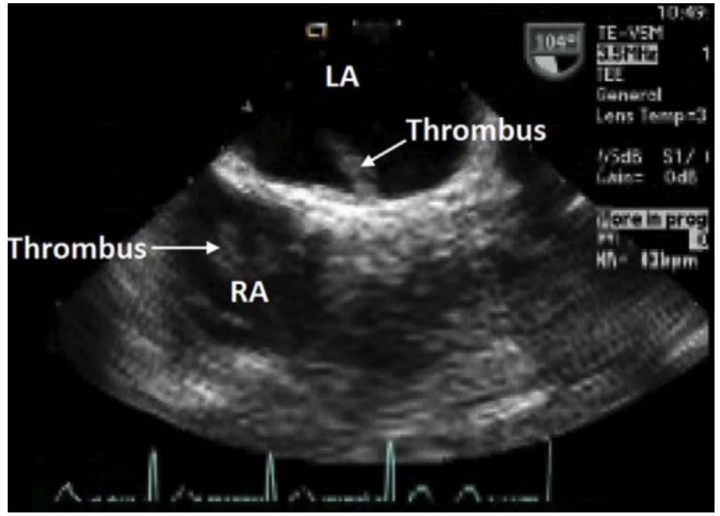

25% of population has a PFO
37% of patients with cryptogenic stroke have a PFO
10% of ischemic strokes in 18-60 years of age are PFO related.

Hagen et al, Mayo Clinic Proc. 1984; 59(1):17
Giannesini et al, Stroke. 1984; 2002

Patent Foramen Ovale Diagnosis

Findings	TTE (n=454)	TEE (n=454)
Treatment relevant		
Reduced left ventricular ejection fraction, ≤35% or qualitative	8 (1.8)	8 (1.8)
Regional wall motion abnormality	19 (4.2)	13 (2.9)
Intracardiac thrombi (ventricle or atrium)	3 (0.7)	5 (1.1)
Severe valve disease	6 (1.3)	7 (1.5)
Signs of endocarditis	1 (0.2)	4 (0.9) †
PFO, age ≤60 or >60 y but meeting PFO closure treatment criteria	28 (6.2)	52 (11.5)
Signs of right ventricular overload	1 (0.2)	1 (0.2)
Signs of cardiomyopathy	3 (0.7)	2 (0.44)
Atrial myxoma	…	…
Total*	64 (14.1)	86 (18.9)
Not treatment relevant		
PFO without treatment consequence	29 (6.4)	42 (9.3)
Mild to moderate valve disease	8 (1.8)	10 (2.2)
Aortic thrombus	…	2 (0.4)
Aortic atheroma or plaques	4 (0.9)	74 (16.3)
Other findings of the aorta (ectasy, aneurysm)	7 (1.5)	6 (1.3)
Other	15 (3.3)	23 (5.1)

Table 1. Transcranial Doppler and Transesophageal Echocardiography for Patent Foramen Ovale Evaluation

			TEE		
		Total	Positive*	Negative	*P* value
TCD	Positive[a]	336	224 (48.6)	112 (24.3)	<.001
	Negative	125	18 (3.9)	107 (23.2)	
	Total	461	242	219	

Thomalla, G., et al, Stroke. 2022; 52:177-84
Park et al, J Neuroimaging. 2021; 31:165-70

PFO Closure for secondary stroke prevention

Table 1. Six Trials of Patent Foramen Ovale Closure for Stroke with Results Published in the *Journal*.*

Trial Name (Year of Publication)	No. of Patients	Mean or Median No. of Years of Follow-up	Comparator	Primary Outcome	Hazard Ratio†	P Value†
Trials with negative findings						
CLOSURE I (2012)[2]	909	2	Antiplatelet therapy, warfarin, or both	Composite of stroke or transient ischemic attack at 2 years, death from any cause during the first 30 days, or death from neurologic causes between 31 days and 2 years after randomization	0.78	0.37
PC (2013)[3]	414	4.1 (PFO closure group), 4.0 (medical-therapy group)	Antiplatelet therapy or anticoagulation‡	Composite of death, stroke, transient ischemic attack, or peripheral embolism	0.63	0.34
RESPECT (2013)[4]	980	2.1	Antiplatelet therapy or warfarin	Composite of recurrent nonfatal ischemic stroke, fatal ischemic stroke, or early death after randomization	0.49	0.08
Trials with positive findings						
Gore REDUCE (2017)[5]	664	3.2	Antiplatelet therapy	Ischemic stroke and new brain infarction on imaging	0.23	0.002
CLOSE (2017)[6]	663	5.3	Antiplatelet therapy or anticoagulation‡	Stroke	0.03	<0.001
RESPECT extended follow-up (2017)[7]	980	5.9	Antiplatelet therapy or warfarin	Composite of recurrent nonfatal ischemic stroke, fatal ischemic stroke, or early death after randomization	0.55	0.046

- Not blinded
- Non embolic lacunar infarcts, TIA
- Low event rate in 2 year follow up
- Low Enrollment, High risk PFO were treated outside the trial
- Excluded patients> 60 years

Ropper, A. NEJM. 2017; 377: 11

The NEW ENGLAND JOURNAL of MEDICINE

EDITORIAL

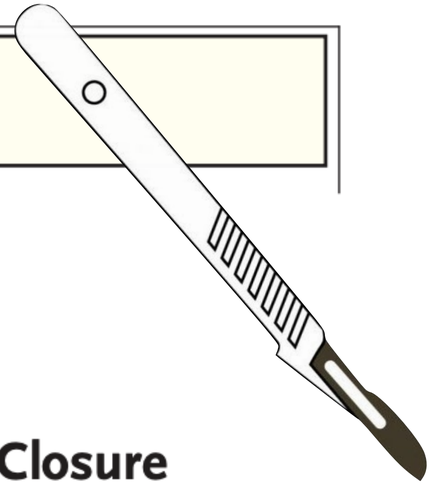

Tipping Point for Patent Foramen Ovale Closure

Allan H. Ropper, M.D.



STARflex



Amplatzer

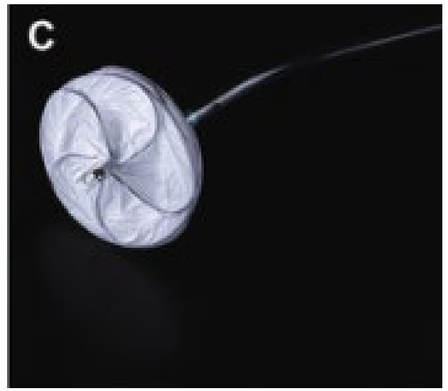

GORE Closure

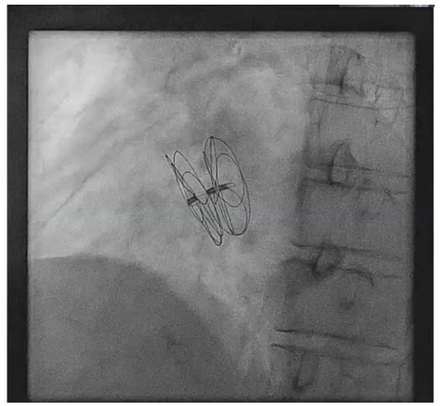

Ropper, A. NEJM. 2017; 377: 11

Complications of PFO Closure

New-Onset AFib

Device Erosion
(<0.2% in first 6 months)

Thrombus formation
(<1% in first 6 months)

Residual Shunt

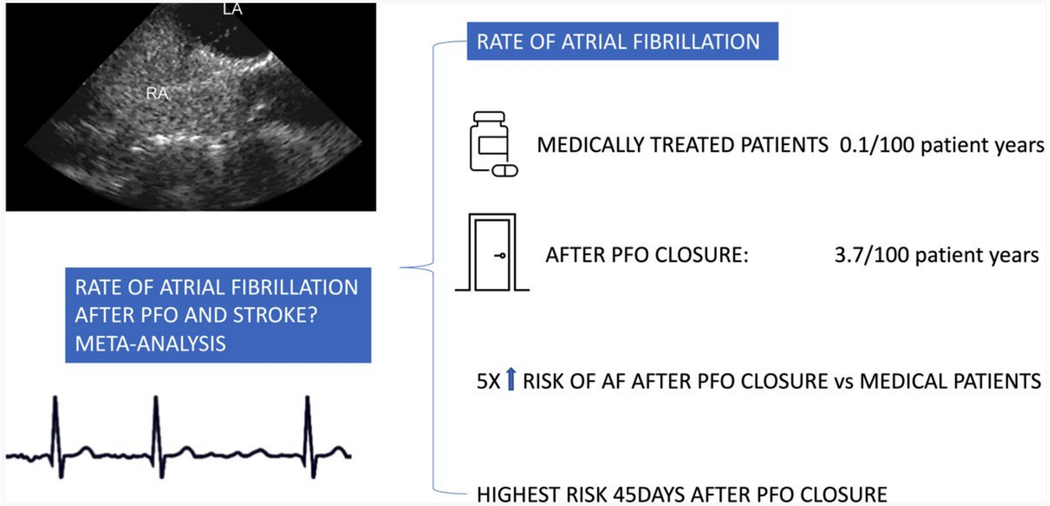

Chen, Z. Stroke. 2021; 1653-61

Risk of Paradoxical Embolism (ROPE Score)

Table 4 RoPE score calculator

Characteristic	Points	RoPE score
No history of hypertension	1	
No history of diabetes	1	
No history of stroke or TIA	1	
Nonsmoker	1	
Cortical infarct on imaging	1	
Age, y		
18-29	5	
30-39	4	
40-49	3	
50-59	2	
60-69	1	
≥70	0	
Total score (sum of individual points)		
Maximum score (a patient <30 y with no hypertension, no diabetes, no history of stroke or TIA, nonsmoker, and cortical infarct)		10
Minimum score (a patient ≥70 y with hypertension, diabetes, prior stroke, current smoker, and no cortical infarct)		0

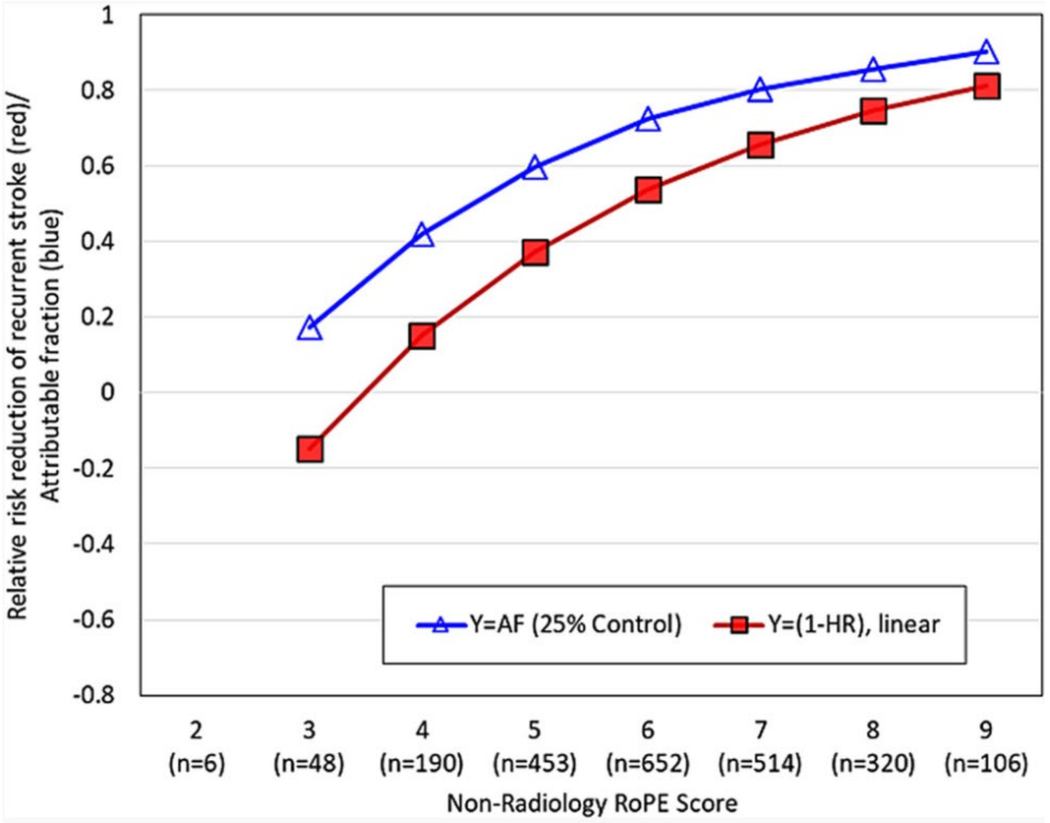

ROPE Score ≥7 - 69% RRR
ROPE Score <7 - 18% RRR

Kent, D. Neurology. 2013; 81: 619-625
Kent, D. Stroke. 2020; 51: 3119-3123

PFO-Associated Stroke Causal Likelihood (PASCAL)

Table 2. Proposed Flexible Clinical Practice Approach to Classifying Patent Foramen Ovale Causal Association in Patients With Embolic Infarct Topography and Without Other Major Stroke Sources[a]

		RoPE Score	
Risk source	Features	Low[b]	High[b]
Very high	A PFO and a straddling thrombus	Definite	Definite
High	(1) Concomitant pulmonary embolism or deep venous thrombosis preceding an index infarct combined with either (2a) a PFO and an atrial septal aneurysm or (2b) a large-shunt PFO	Probable	Highly probable
Medium	Either (1) a PFO and an atrial septal aneurysm or (2) a large-shunt PFO	Possible	Probable
Low	A small-shunt PFO without an atrial septal aneurysm	Unlikely	Possible

Abbreviations: PFO, patent foramen ovale; RoPE, the Risk of Paradoxical Embolism Score.

[a] The algorithm in this table is proposed for use in flexible clinical practice, when application of an entire formal classification system is not being conducted.

[b] The RoPE score includes points for 5 age categories, cortical infarct, absence of hypertension, diabetes, prior stroke or transient ischemic attack, and smoking. A higher RoPE score (≥7 points) increases probability of causal association.

Elgendy, A. JAMA Neurol. 2020; 878-886

Heterogeneity of Treatment Effect

3740 patients
Median follow up 57 months
Annualized incident stroke-
Medical Rx 1.09%
PFO Closure- 0.47%

Figure 2. Recurrent Ischemic Stroke Heterogeneity of Treatment Effect (HTE) Analyses for RoPE and PASCAL

A Hazard ratios of the primary outcome of recurrent ischemic stroke

	Device, overall events/No. of patients	Medical therapy, overall events/ No. of patients	Hazard ratio (95% CI)	P value for interaction
RoPE categories				
<7	29/700	41/704	0.61 (0.37 to 1.00)	.02
≥7	11/1189	41/1147	0.21 (0.11 to 0.42)	
PASCAL categories				
Unlikely	17/293	11/254	1.14 (0.53 to 2.46)	
Possible	19/897	46/914	0.38 (0.22 to 0.65)	.003
Probable	3/700	25/683	0.10 (0.03 to 0.35)	

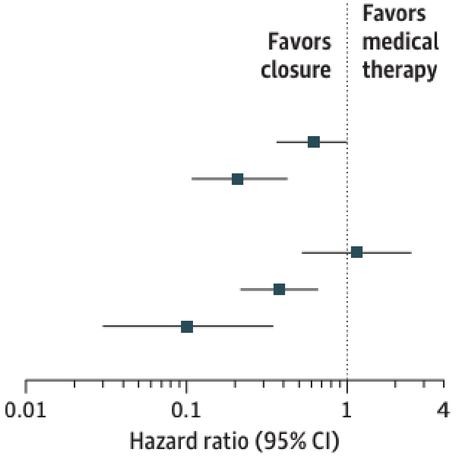

B Absolute risk reductions of the primary outcome of recurrent ischemic stroke

	Device, 2-y events/No. (%)	Medical therapy, 2-y events/ No. (%)	Absolute risk reduction at 2 y (95% CI)	No. needed to treat (95% CI)
RoPE categories				
<7	20/700 (2.9)	27/704 (4.0)	1.1 (-0.9 to 3.1)	91 (-112 to 32)
≥7	7/1189 (0.6)	28/1147 (2.6)	2.1 (1.0 to 3.1)	49 (100 to 32)
PASCAL categories				
Unlikely	11/293 (4.1)	8/254 (3.4)	-0.7 (-4.0 to 2.6)	-153 (-25 to 38)
Possible	13/897 (1.5)	31/914 (3.6)	2.1 (0.6 to 3.6)	47 (166 to 27)
Probable	2/700 (0.3)	16/683 (2.5)	2.1 (0.9 to 3.4)	47 (111 to 29)

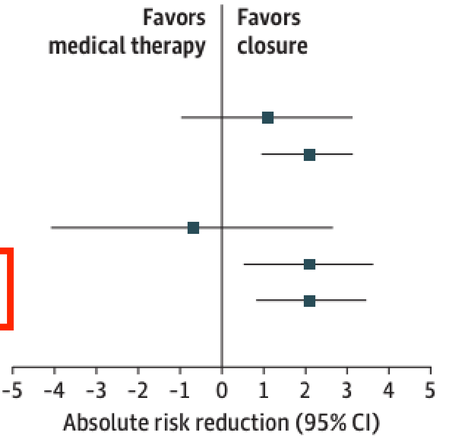

Afib Detection

4.41%
1.53%
0.65%

Kent, D. JAMA. 2021; 326(22): 2277-2286

PFO Closure for Migraine With Aura

TABLE 3 | The Effect of Patent Foramen Ovale Closure on Migraine in randomized controlled studies.

	Subjects	Mean age	Diagnostic mode	Randomization	Follow-up	Result					Antiplatelet therapy
						Primary endpoint	Secondary endpoints			Exploratory analysis	
MIST trial	MA with frequent attacks, failed ≥2 prophylactic treatments, moderate or large RLS with PFO		cTTE, TEE		180 days	Cessation of migraine headache	Frequency of attack reduction (days/month)	Total MIDAS score	Total HIT-6 score	Reduction in total migraine headache days (excluding 2 outliers)	Aspirin and clopidogrel were given 300 mg in the 24 h before the procedure and 75 mg each daily for 90 days after the procedure
Intervention group	74	44.3 ± 10.6		STARFlex septal repair implant		3	3.26 ± 1.82	16 (0–270)	60 ± 10		
Control group	73	44.6 ± 10.4		Sham procedure (skin incision in the groin)		3	3.55 ± 2.14	18 (0–240)	59 ± 8.8		
P						1	0.13	0.89	0.79	0.027	
										Post-hoc analyses	
PRIMA	Unresponsive to 2 preventive medications MA with PFO		cTTE or cTEE and TEE		1 year	Reduction migraine (days/month)	The average attacks reduction	≥50% reduction of migraine days	MIDAS score improvement	Mean reduction in MA (days/month)	Aspirin 75–100 mg/day for 6 months, clopidogrel 75 mg/day for 3 months
Intervention group	53	44.1 ± 10.7		Amplatzer PFO Occluder		−2.9	−2.1	15 (38%)	−18.3	−2.4	
Control group	54	42.7 ± 11.0		Medical management		−1.7	−1.3	6 (15%)	−13.9	−0.6	
P						0.17	0.97	0.0189	0.53	0.0141	
PREMIUM	Failed ≥3 preventive medications, 6–14 days/month migraine with RLS		cTCD, cTTE		1 year	50% reduction in attacks	Number of migraine (days/month)	≥75% reduction in migraine attacks	Complete cessation of migraine attacks		Pre-treated with aspirin 325 mg and clopidogrel 600 mg
Intervention group	117	42 ± 10		Amplatzer PFO Occluder		45 (38.5%)	−3.4 ± 4.4	24 (20.5%)	10 (8.5)%		
Control group	103	41 ± 10		sham procedure		33 (32%)	−2.0 ± 5.0	17 (16.5%)	1 (1%)		
P						0.32	0.025	0.45	0.01		

MA, migraine with aura.

Chen, Z. Stroke. 2021; 1653-61

Patient 2 *(post).*

Ms. A is a 55 year old woman with no past history apart from **morbid obesity and migraine with aura** that appears to be well controlled with Erenumab (*aimovig*), presents to ED with acute onset right hand weakness. CT Angiogram of head and neck is normal apart from mild calcifications at bilateral carotid bifurcation. MRI of the brain showed a **small cortical infarct involving the left hand knob area (image)**. A trans-thoracic echocardiogram was normal but a **trans-esophageal echocardiogram showed a small PFO**. She neither has evidence of venous thrombosis in lower extremity, nor a pro coagulable state. Which of the following is the best answer for this patient ?

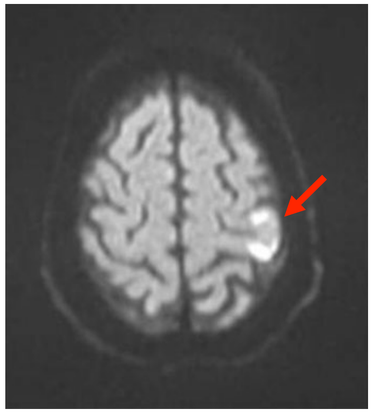

A. No PFO Closure because the PFO is small.
B. Aspirin, Statin, Cardiac monitoring for detection of occult atrial fibrillation.
C. Anticoagulation because cortical strokes are embolic.
D. Close PFO. PFO closure also helps treatment of migraine with aura.

slido

Which of the following is the best answer for this patient ?

ⓘ Start presenting to display the poll results on this slide.

Patient 2 *(brainstorm).*

Ms. A is a 55 year old woman with no past history apart from **morbid obesity and migraine with aura** that appears to be well controlled with Erenumab (*aimovig*), presents to ED with acute onset right hand weakness. CT Angiogram of head and neck is normal apart from mild calcifications at bilateral carotid bifurcation. MRI of the brain showed a **small cortical infarct involving the left hand knob area (image)**. A trans-thoracic echocardiogram was normal but a **trans-esophageal echocardiogram showed a small PFO**. She neither has evidence of venous thrombosis in lower extremity, nor a pro coagulable state. Which of the following is the best answer for this patient ?

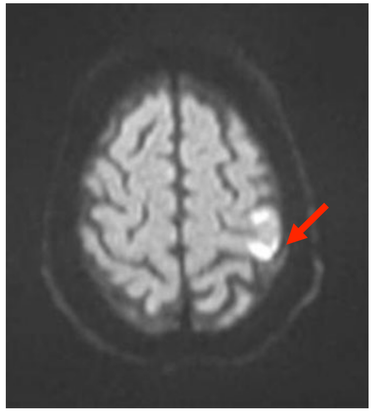

Table 4 RoPE score calculator

Characteristic	Points	RoPE score
No history of hypertension	1	
No history of diabetes	1	
No history of stroke or TIA	1	
Nonsmoker	1	
Cortical infarct on imaging	1	
Age, y		
18-29	5	
30-39	4	
40-49	3	
50-59	2	
60-69	1	
≥70	0	
Total score (sum of individual points)		7
Maximum score (a patient <30 y with no hypertension, no diabetes, no history of stroke or TIA, nonsmoker, and cortical infarct)		10
Minimum score (a patient ≥70 y with hypertension, diabetes, prior stroke, current smoker, and no cortical infarct)		0

Table 2. Proposed Flexible Clinical Practice Approach to Classifying Patent Foramen Ovale Causal Association in Patients With Embolic Infarct Topography and Without Other Major Stroke Sources[a]

		RoPE Score	
Risk source	Features	Low[b]	High[b]
Very high	A PFO and a straddling thrombus	Definite	Definite
High	(1) Concomitant pulmonary embolism or deep venous thrombosis preceding an index infarct combined with either (2a) a PFO and an atrial septal aneurysm or (2b) a large-shunt PFO	Probable	Highly probable
Medium	Either (1) a PFO and an atrial septal aneurysm or (2) a large-shunt PFO	Possible	Probable
Low	A small-shunt PFO without an atrial septal aneurysm	Unlikely	Possible

Abbreviations: PFO, patent foramen ovale; RoPE, the Risk of Paradoxical Embolism Score.

[a] The algorithm in this table is proposed for use in flexible clinical practice, when application of an entire formal classification system is not being conducted.

[b] The RoPE score includes points for 5 age categories, cortical infarct, absence of hypertension, diabetes, prior stroke or transient ischemic attack, and smoking. A higher RoPE score (≥7 points) increases probability of causal association.

Patient 2 *(brainstorm).*

Ms. A is a 55 year old woman with no past history apart from **morbid obesity and migraine with aura** that appears to be well controlled with Erenumab (*aimovig*), presents to ED with acute onset right hand weakness. CT Angiogram of head and neck is normal apart from mild calcifications at bilateral carotid bifurcation. MRI of the brain showed a **small cortical infarct involving the left hand knob area (image)**. A trans-thoracic echocardiogram was normal but a **trans-esophageal echocardiogram showed a small PFO**. She neither has evidence of venous thrombosis in lower extremity, nor a pro coagulable state. Which of the following is the best answer for this patient ?

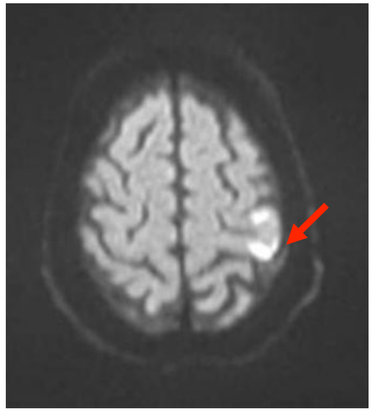

A. ~~No PFO Closure because the PFO is small.~~ Attributable causal risk (PASCAL) is still high “Possible” due to high ROPE score.

B. ~~Aspirin, Statin, Cardiac monitoring for detection of occult atrial fibrillation.~~This may not provide adequate stroke prevention. Sleep study to evaluate for OSA and cardiac monitoring post-closure may still be relevant as untreated OSA increases risk of AFib. PFO closure increases risk of Afib 5 fold.

C. ~~Anticoagulation because cortical strokes are embolic.~~There is no evidence in favor of presumptive anticoagulation based on stroke location. NAVIGATE ESUS and RESPECT ESUS trials.

D. **Close PFO. PFO closure also helps treatment of migraine with aura.** The benefit of PFO closure in migraine with aura is dose dependent and may be justified in intractable migraines with large PFO.

Patient 2
(answer).

Ms. A is a 55 year old woman with no past history apart from **morbid obesity and migraine with aura** that appears to be well controlled with Erenumab (*aimovig*), presents to ED with acute onset right hand weakness. CT Angiogram of head and neck is normal apart from mild calcifications at bilateral carotid bifurcation. MRI of the brain showed a **small cortical infarct involving the left hand knob area (image)**. A trans-thoracic echocardiogram was normal but a **trans-esophageal echocardiogram showed a small PFO**. She neither has evidence of venous thrombosis in lower extremity, nor a pro coagulable state. Which of the following is the best answer for this patient ?

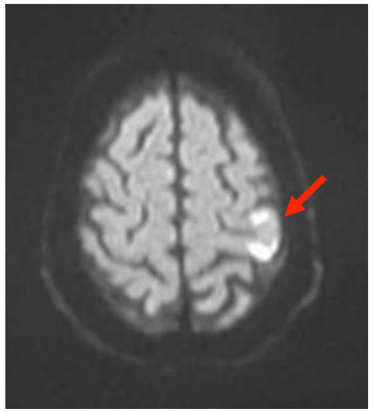

A. No PFO Closure because the PFO is small.
B. Aspirin, Statin, Cardiac monitoring for detection of occult atrial fibrillation.
C. Anticoagulation because cortical strokes are embolic.
D. Close PFO. PFO closure also helps treatment of migraine with aura.

Patient 3 *(pre).*

Mr. A is a 85 year old high functioning man with HTN, HLD, **chronic Afib on Apixaban**, and several old strokes but no residual deficits. He presents to ED with left hemiparesis and is found to have a **right putaminal hemorrhage**. He was on **Rivaroxaban** in the past but experienced **GI bleeding** requiring blood transfusions. The patient is discharged to an acute rehab after 1 week of hospitalization. Which of these is preferred long term management in this patient after discharge?

A. Continue aspirin indefinitely for secondary stroke prevention.
B. Switch to Edoxaban given bleeding events with both Apixaban and Rivaroxaban.
C. Resume Apixaban in 4 weeks and refer for left atrial appendage closure.
D. Resume anticoagulation with lower dose of Apixaban.

slido

Which of these is preferred long term management in this patient after discharge?

ⓘ Start presenting to display the poll results on this slide.

Prevalence of Atrial Fibrillation

Figure 2. Prevalence of Diagnosed Atrial Fibrillation Stratified by Age and Sex

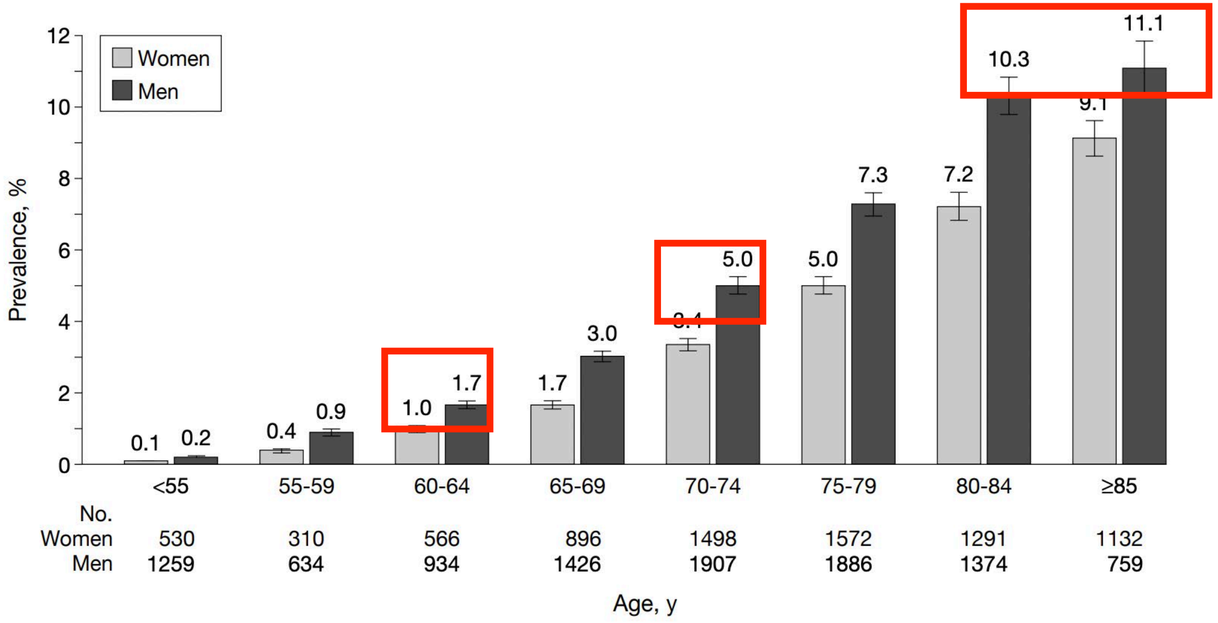

Errors bars represent 95% confidence intervals. Numbers represent the number of men and women with atrial fibrillation in each age category.

Figure 3. Projected Number of Adults With Atrial Fibrillation in the United States Between 1995 and 2050

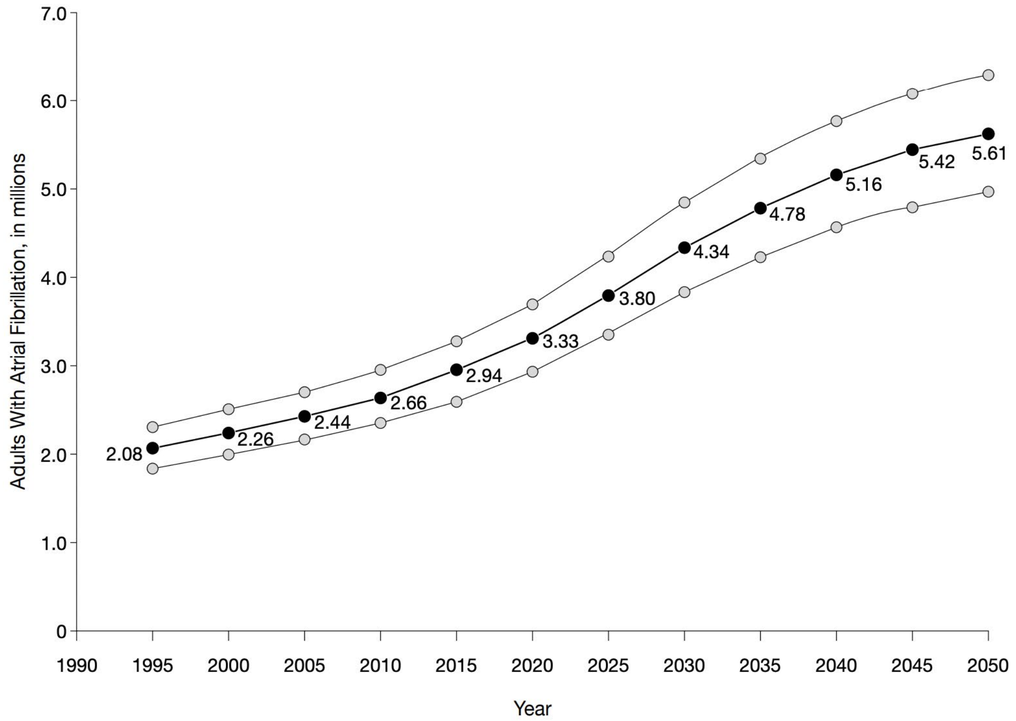

Prevalence of Afib in US is predicted to double by 2050

Go, A., et al. JAMA, 2001. 285(18) : 2370-75

Anticoagulation for AFib Treatment

Risk	Apixaban	Dabigatran	Rivaroxaban	Warfarin
Trial (vs warfarin)	ARISTOTLE	RE-LY	ROCKET-AF	--
Ischemic stroke	[HR] 0.92	**[RR] 0.76***	[HR] 0.94	[HR] 1; [RR] 1
ICH	**[HR] 0.42***	**[RR] 0.41***	**[HR] 0.67***	[HR] 1; [RR] 1
Major bleeding+	**[HR] 0.69***	[RR] 0.93	[HR] 1.02	[HR] 1; [RR] 1
Systemic embolism	[HR] 0.87	**[RR] 0.74***	**[HR] 0.19***	[HR] 1; [RR] 1
Acute MI	[HR] 0.61	[RR] 1.27	[HR] 0.81	[HR] 1; [RR] 1
GI bleeding	[HR] 0.89	**[RR] 1.48***	**[HR] 1.46***	[HR] 1; [RR] 1
All-cause Mortality	**[HR] 0.89***	[RR] 0.88	[HR] 0.85	[HR] 1; [RR] 1

*Statistically significant

+Major bleeding as defined by ISTH. Concomitant use of antiplatelet increases absolute risk of major bleeding without affecting relative benefits of NOACs. Deteriorating renal function increases risk of stroke and major bleeding

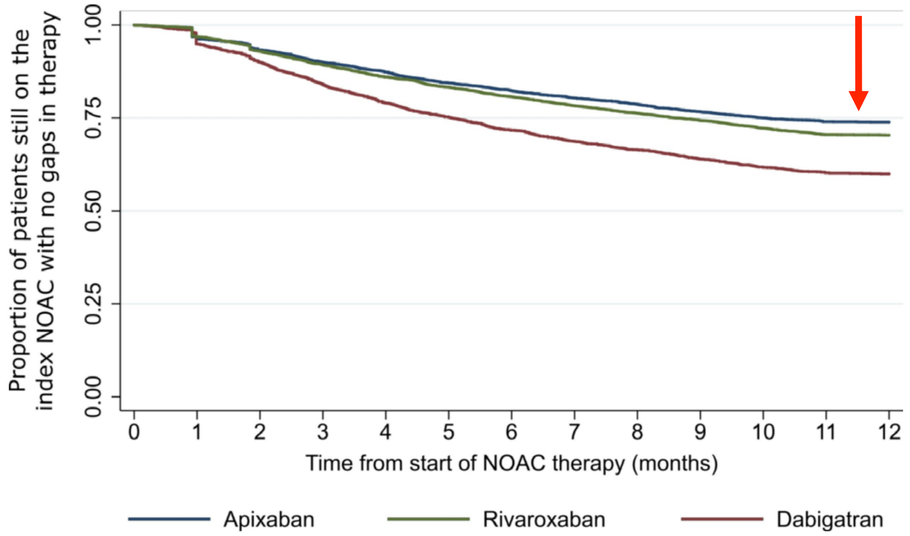

25% of patients would have discontinued using DOAC by the end of first year.

British Journal of Clinical Pharmacology

Editors' view

Warfarin: almost 60 years old and still causing problems

- Non-compliance
- Financial Burden
- Elderly, Falls
- History of bleeding or predisposition
- Abnormal Hepatic/ Renal Profile
- Thrombocytopenia/ Cancer related bleeding
- Concomitant use of drugs/ alcohol
- Occupation/ life style

Ruigómez A, et al. BMJ Open 2019;9:e031342.

Left Atrial Appendage: Most Lethal Human Attachment

CHICKEN WING
Most Common

CAULIFLOWER
Highest Embolic Potential

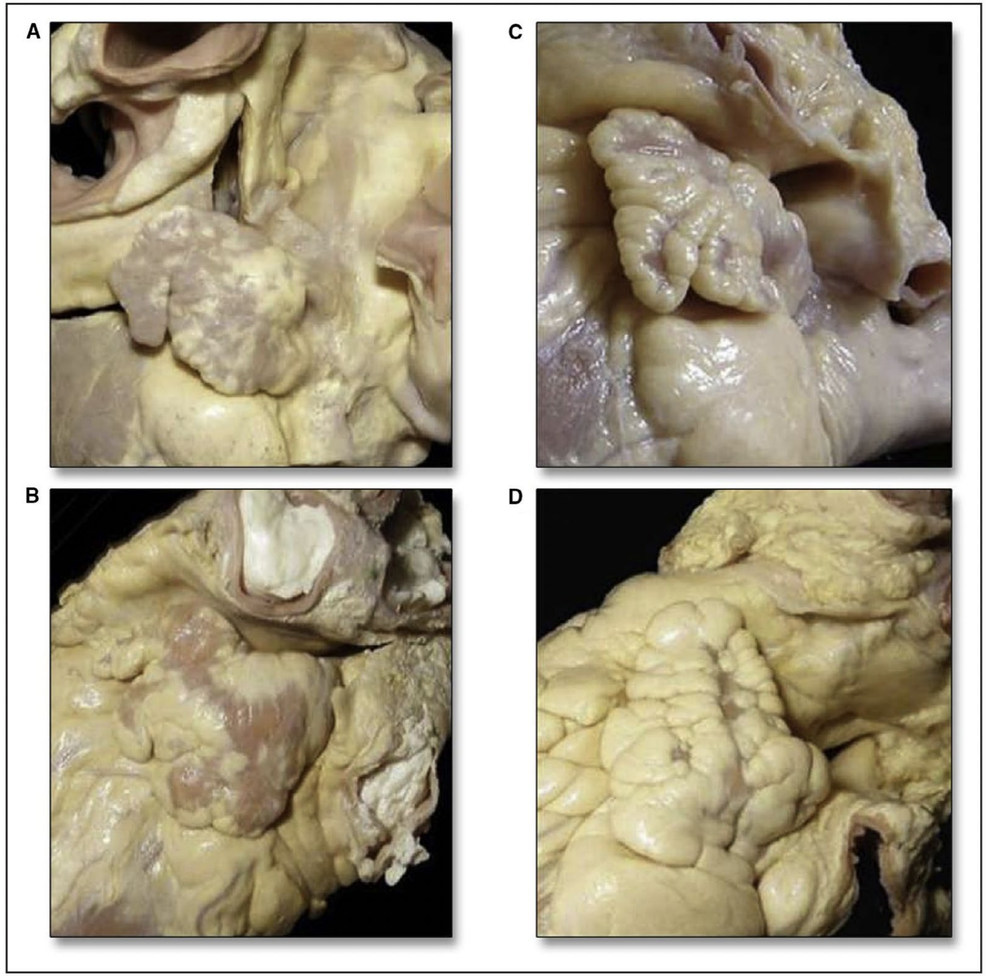

WIND SOCK
Least Common

CACTUS
Second Most Common

57% of patients with valvular Afib had thrombi in LAA
91% of thrombi in non valvular Afib had thrombi in LAA

Beigel, R. JACC Cardiovascular Imaging. 2014; 7:1251-65
Collado, F., et al. ; JAHA. 2021

Left Atrial Appendage Closure Device

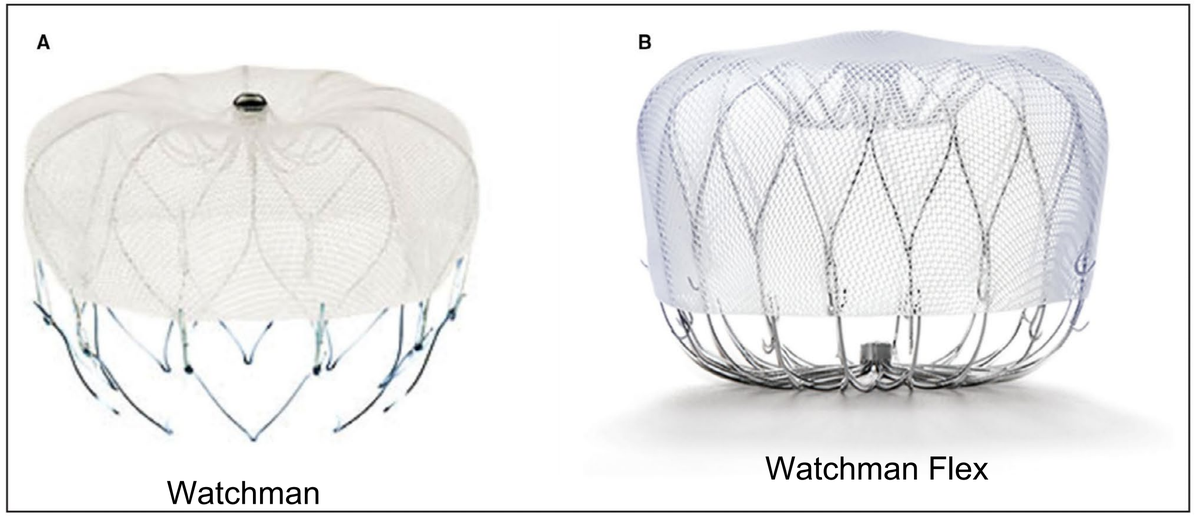

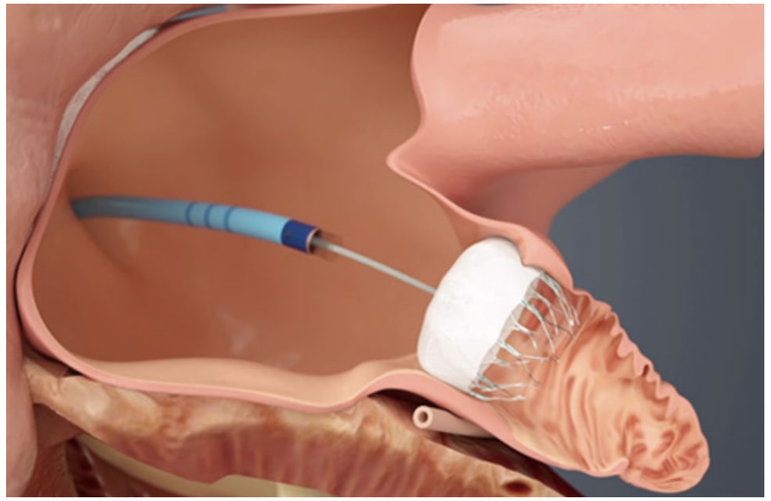

Amulet

Lariat

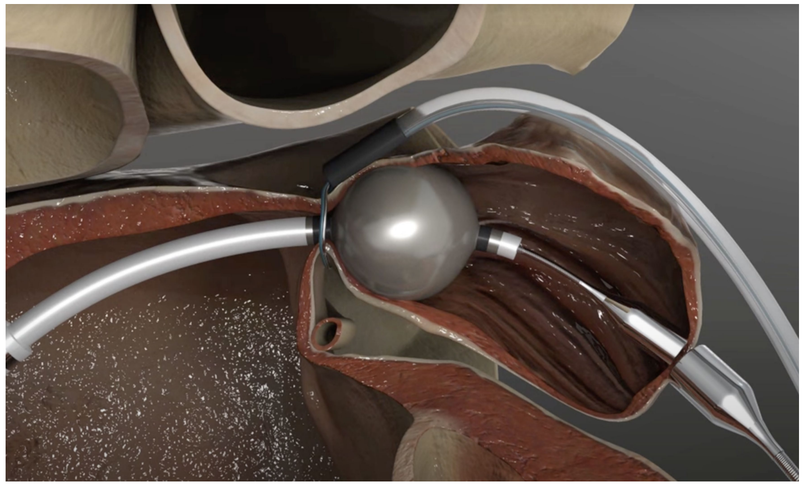

Left Atrial Appendage Closure Procedure

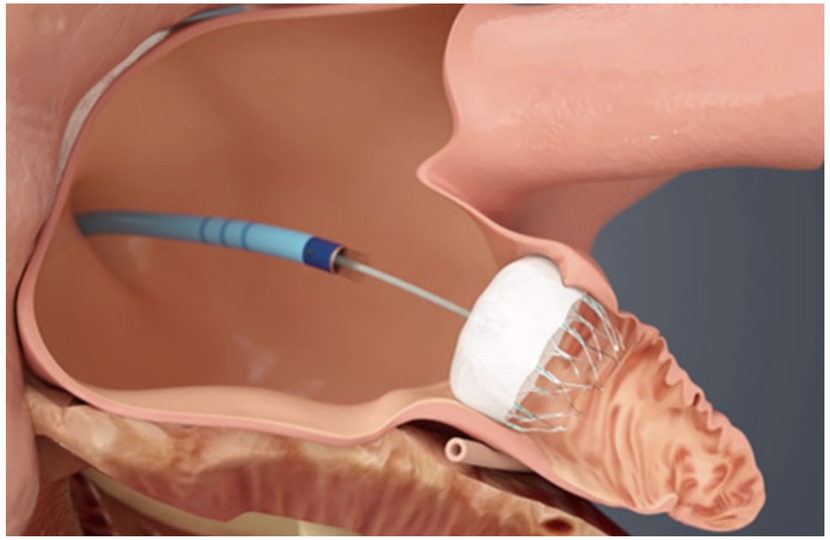

Position, Anchor, Size, Seal

Contraindications

- Intracradiac thrombus
- ASD/PFO Closure Device
- LAA Anatomy
- Occluded IVC
- Infection
- Contraindication to short term anticoagulation
- Life expectancy < 1 year

Aspirin 81 + Warfarin x 45 Days

↓

LAA Seal adequate (<5 mm) CT/ TEE at 45 days

↓

Aspirin 325 + Clopidogrel x 6 months

↓

Aspirin 325 Indefinitely

Complications

- Pericardial Effusion
- Peridevice Leak
- Device Embolization
- Device related thrombus

LAA Closure vs Anticoagulation for Afib

PROTECT AF

Watchman vs Warfarin

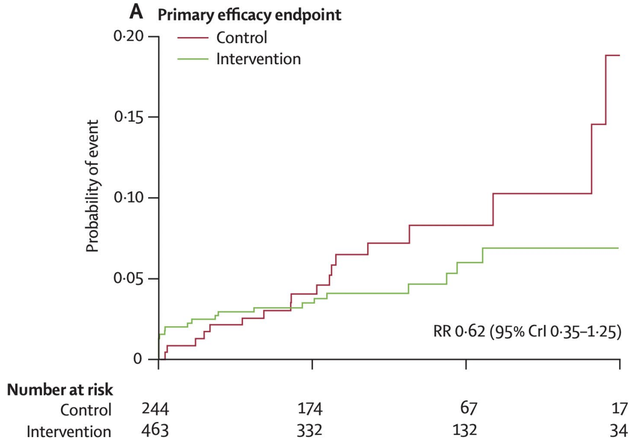

	Intervention (n=463)	Control (n=244)
Serious pericardial effusion*	22 (4·8%)	0
Major bleeding†	16 (3·5%)	10 (4·1%)
Procedure-related ischaemic stroke	5 (1·1%)	0
Device embolisation	3 (0·6%)	0
Haemorrhagic stroke‡	1 (0·2%)	6 (2·5%)
Other§	2 (0·4%)	0

Holmes, D., et al. ; Lancet. 2009

PREVAIL

Watchman vs Warfarin

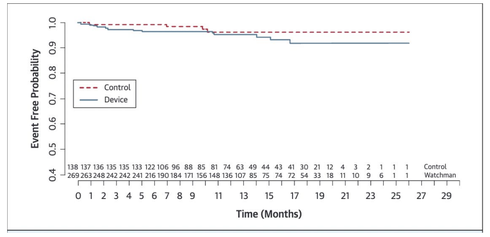

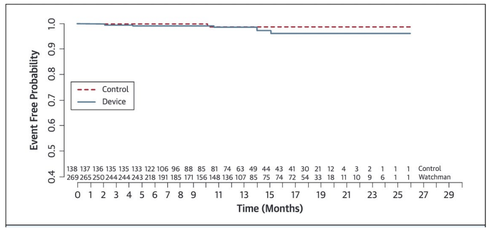

TABLE 3 Coprimary Efficacy Endpoint Observed Events by Type: PREVAIL Subjects Only (Intention-to-Treat)*

	Device Group			Control Group		
	No. of Events	% of Subjects	% of Endpoints	No. of Events	% of Subjects	% of Endpoints
Ischemic stroke	5	1.9	35.7	1	0.7	25.0
Hemorrhagic stroke	1	0.4	7.1	0	0.0	0.0
Death (cardiovascular/unexplained)	7	2.6	50.0	3	2.2	75.0
Systemic embolism	1	0.4	7.1	0	0.0	0.0

Holmes, D., et al. ; JACC. 2014

PRAGUE-17

Watchman/ Amulet vs DOAC

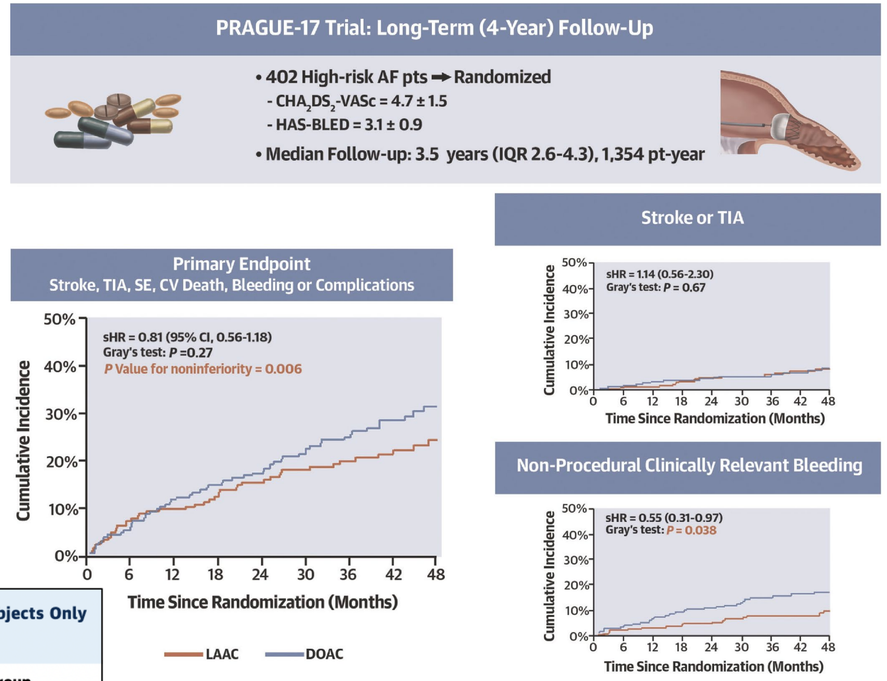

Osmanick, P. , et al. ; JACC. 2022

LAA Closure vs Anticoagulation for Afib

PROTECT AF	PREVAIL	PRAGUE-17
Watchman vs Warfarin	Watchman vs Warfarin	Watchman/ Amulet vs DOAC

FIGURE 1 Clinical Outcomes

Summary Plot of Clinical Outcomes

	LAAC	OAC	Risk Ratio	95% CI	p Value
All Stroke or SE	6.1% (57/933)	5.8% (34/583)	0.98	0.65–1.48	0.92
Ischemic Stroke or SE	5.6% (52/933)	3.6% (21/583)	1.48	0.89–2.46	0.13
Ischemic Stroke or SE >7 days	4.7% (44/933)	3.6% (21/583)	1.27	0.76–2.14	0.37
Hemorrhagic Stroke	0.5% (5/933)	2.4% (14/583)	0.22	0.08–0.58	0.002
Cardiovascular Mortality	5.4% (50/933)	8.2% (48/583)	0.65	0.44–0.95	0.03
All-Cause Mortality	14.3% (133/933)	17.8% (104/583)	0.78	0.62–0.99	0.04
Major Bleeding	10.5% (98/933)	11% (64/583)	0.89	0.66–1.20	0.46
Nonprocedure-Related Major Bleeding	6.2% (58/933)	11.1% (65/583)	0.53	0.38–0.74	0.0002

Turagam, M., et al. ; JACC. 2020

LAA Closure vs Anticoagulation for Afib

PROTECT AF	PREVAIL	PRAGUE-17
Watchman vs Warfarin	Watchman vs Warfarin	Watchman/ Amulet vs DOAC

FIGURE 1 Clinical Outcomes

Summary Plot of Clinical Outcomes

	LAAC	OAC	Risk Ratio	95% CI	p Value
All Stroke or SE	6.1% (57/933)	5.8% (34/583)	0.98	0.65–1.48	0.92
Ischemic Stroke or SE	5.6% (52/933)	3.6% (21/583)	1.48	0.89–2.46	0.13
Ischemic Stroke or SE >7 days	4.7% (44/933)	3.6% (21/583)	1.27	0.76–2.14	0.37
Hemorrhagic Stroke	0.5% (5/933)	2.4% (14/583)	0.22	0.08–0.58	0.002
Cardiovascular Mortality	5.4% (50/933)	8.2% (48/583)	0.65	0.44–0.95	0.03
All-Cause Mortality	14.3% (133/933)	17.8% (104/583)	0.78	0.62–0.99	0.04
Major Bleeding	10.5% (98/933)	11% (64/583)	0.89	0.66–1.20	0.46
Nonprocedure-Related Major Bleeding	6.2% (58/933)	11.1% (65/583)	0.53	0.38–0.74	0.0002

Turagam, M., et al. ; JACC. 2020

Patient 3 *(post).*

Mr. A is a 85 year old high functioning man with HTN, HLD, **chronic Afib on Apixaban**, and several old strokes but no residual deficits. He presents to ED with left hemiparesis and is found to have a **right putaminal hemorrhage**. He was on **Rivaroxaban** in the past but experienced **GI bleeding** requiring blood transfusions. The patient is discharged to an acute rehab after 1 week of hospitalization. Which of these is preferred long term management in this patient after discharge?

A. Continue aspirin indefinitely for secondary stroke prevention.
B. Switch to Edoxaban given bleeding events with both Apixaban and Rivaroxaban.
C. Resume Apixaban in 4 weeks and refer for left atrial appendage closure.
D. Resume anticoagulation with lower dose of Apixaban.

slido

Which of these is preferred long term management in this patient after discharge?

ⓘ Start presenting to display the poll results on this slide.

Patient 3 *(brainstorm).*

Mr. A is a 85 year old high functioning man with HTN, HLD, **chronic Afib on Apixaban**, and several old strokes but no residual deficits. He presents to ED with left hemiparesis and is found to have a **right putaminal hemorrhage**. He was on **Rivaroxaban** in the past but experienced **GI bleeding** requiring blood transfusions. The patient is discharged to an acute rehab after 1 week of hospitalization. Which of these is preferred long term management in this patient after discharge?

A. ~~Continue aspirin indefinitely for secondary stroke prevention.~~ Aspirin does not provide adequate prevention for Afib related strokes. **ASPIRE trial** is currently enrolling.

B. ~~Switch to full dose Edoxaban given bleeding events with both Apixaban and Rivaroxaban.~~ There is some evidence for safety of low dose Edoxaban in elderly who are not appropriate for anticoagulation. **ELDERCARE AF.**

C. Resume Apixaban in 4 weeks and refer for left atrial appendage closure.

D. ~~Resume anticoagulation with lower dose of Apixaban.~~ No evidence to support this.

Patient 3
(answer).

Mr. A is a 85 year old high functioning man with HTN, HLD, **chronic Afib on Apixaban**, and several old strokes but no residual deficits. He presents to ED with left hemiparesis and is found to have a **right putaminal hemorrhage**. He was on **Rivaroxaban** in the past but experienced **GI bleeding** requiring blood transfusions. The patient is discharged to an acute rehab after 1 week of hospitalization. Which of these is preferred long term management in this patient after discharge?

A. Continue aspirin indefinitely for secondary stroke prevention.
B. Switch to Edoxaban given bleeding events with both Apixaban and Rivaroxaban.
C. Resume Apixaban in 4 weeks and refer for left atrial appendage closure.
D. Resume anticoagulation with lower dose of Apixaban.

Atrial Fibrillation Ablation

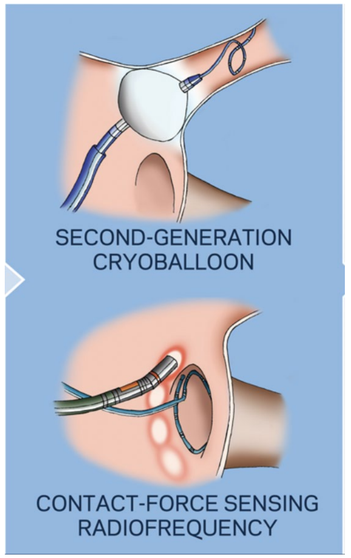

Table. Randomized Studies Comparing Catheter Ablation vs Medical Treatment Alone and Providing Data on the Risk of Stroke

Author, Reference	Sample Size (Patients)		No. of Events			
			Ablation		No Ablation	
	Ablation	No Ablation	Stroke	Death	Stroke	Death
	2485	2237	21	91	23	120

Paradoxical Lack of Evidence

- Absolute stroke rates are low in appropriately anti coagulated contemporary Afib patients. Large relative reductions in stroke risk with ablation translates into tiny net benefit.
- Residual risk may relate to non cardio-embolic lacunar strokes, where Afib ablation may not be beneficial.
- Short Silent Afib despite ablation may be still impact stroke risk.
- Atrial Remodeling (Cardiopathy) is still unaffected by Afib ablation.

Afib ablation may reduce rates of hospitalization and cardiac events and must be pursued when indicated but there is not stroke benefit.

Berra, S., et al. ; Stroke 2019; 50:2970-2976

Institutional Volume at University of Kentucky

Jennifer Vissing
Nurse Coordinator

Andrew Leventhal
Interventional Cardiologist

Naoki Misumida
Interventional Cardiologist

John Gurley
Interventional Cardiologist

859-323-0295

	Annual
PFO Closure	60
LAA Closure	80-100

Take home message

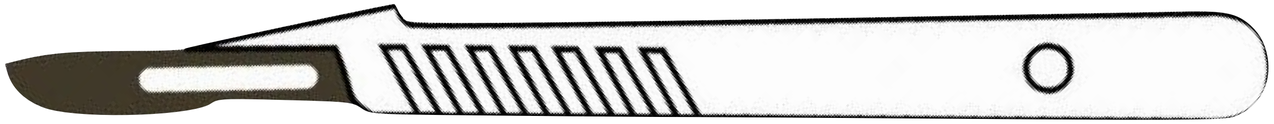

1.Carotid revascularization in addition to medical treatment is indicated for symptomatic carotid stenosis within 2 weeks of the incident event. Medical treatment is the preferred treatment for asymptomatic carotid stenosis although surgery can be considered only in highly selected patients.

2.The selection of patients for PFO closure is preferably based on a multivariable causal classification system that accounts for cerebrovascular risk factors as well as echocardiogram findings.

3.Left Atrial Appendage Closure can be considered for patients with AFib who do not tolerate long-term anticoagulation, especially after intracerebral hemorrhage.

4.**Although new surgical methods for secondary stroke prevention have emerged in the last two decades, real wisdom lies in knowing when not to operate**.